

# Periorificial dermatitis in children

Margarita Larralde<sup>1</sup>, Maria Eugenia Abad<sup>2</sup>, Paula Luna<sup>3</sup>, Romina Plafnik<sup>4</sup>, Betina Pagotto<sup>4</sup>

## Abstract

Periorificial dermatitis is a recurrent papulopustular eruption located in perioral, perinasal, or periocular regions, and seldom in vulvar area. It has been described in association with the use of topical or inhaled corticosteroids, moisturizing creams, fluoride toothpastes, topical antibiotics, sun blockers, among other agents.

**Objective:** To describe clinical presentation, association with the use of topical or inhaled corticosteroids, and treatment in patients with periorificial dermatitis.

**Material and Method:** Descriptive, retrospective study at the Pediatric Dermatology Section of Hospital Ramos Mejía.

**Results:** A total of 48 patients with diagnosis of periorificial dermatitis were evaluated between 1986 and 2008. Sixty percent of the cases were female. Average age was 8.4 years. Most frequent location was perioral (41.7 percent), followed by perioral and perinasal location (25 percent). Only 4 patients had perivulvar lesions, 3 of them without previous use of corticosteroids. Use of topical or inhaled corticosteroids was observed in 66.6 percent of patients for an average period of 2 years. Most cases received metronidazole and erythromycin as topical, systemic, or combined treatment.

**Conclusion:** Higher incidence of periorificial dermatitis was observed in association with the use of topical and inhaled corticosteroids. Inhaled corticosteroids were associated with perioral and perinasal locations. Perivulvar location was not associated with the use of corticosteroids. Lesions appeared earlier with the use of topical corticosteroids. (*Dermatol Argent* 2009; 15(4):267-271).

**Key words:** periorificial dermatitis, perioral dermatitis, steroids.

**Reception date:** 12/5/09 | **Approval date:** 15/7/09

1. Head of the Dermatology Department, Hospital Alemán. Buenos Aires, Argentine. Head of Pediatric Dermatology Section, Hospital "JM Ramos Mejía", Buenos Aires, Argentine.
2. Physician of the Pediatric Dermatology Section, Hospital "JM Ramos Mejía". Physician of the Dermatology Department, Hospital Alemán.
3. Physician of the Dermatology Department of the Police Medical Complex "Churrucá-Visca", Buenos Aires, Argentine. Physician of the Superior Course of Pediatric Dermatology. Pediatric Dermatology Section, Hospital "JM Ramos Mejía", Buenos Aires, Argentine.
4. Physician of the Superior Course of Pediatric Dermatology. Pediatric Dermatology Section, Hospital "JM Ramos Mejía", Buenos Aires, Argentine.

## Correspondence

Betina Pagotto: Charcas 3028 Piso 6to D, (1485) Autonomous City of Buenos Aires, Argentine Republic | [betina.pagotto@gmail.com](mailto:betina.pagotto@gmail.com)

## Introduction

Periorificial dermatitis (PD), also known as perioral dermatitis, is a relatively frequent dermatosis of increasing incidence in recent years. Although more common in adults and in females, it may also appear in childhood, mainly in prepuberal age.<sup>1</sup> It is characterized by the presence of papules and pustules over an erythematous base, of periorificial distribution with tendency to be confluent, and they may be pruriginous.<sup>1,2</sup>

Etiopathogenesis is ill-defined; its course is benign and mostly limited, without involvement of the patient's general condition. Suitable treatment is topic or systemic antibiotics, and discontinuation of the triggering factor.

In this study, we describe PD clinical and epidemiological features in our pediatric population.

## Materials and method

A descriptive, retrospective, transversal section study was conducted in the Pediatric Dermatology Section of Hospital Ramos Mejía. Clinical records were reviewed from year 1986 to 2008. All patients from 0 to 18 years old having typical periorificial dermatitis, with the presence of papules

or pustules located on perioral, perinasal, periocular, or vulvar areas were included whereas patients with diagnosis of contact dermatitis, atopic dermatitis, perianal, acne y rosacea were excluded. Inclusion criteria were met by 52 patients. Before data analysis, 4 patients with insufficient clinical record data were excluded. In the remaining 48 patients, age, gender, lesion distribution, history of topic or inhaled corticosteroid use, lapse of lesion appearance after using corticosteroids, and treatment data were collected.

## Results

Included in the study were 48 patients with diagnosis of periorificial dermatitis, whereof 29 (60 percent) were female, and 19 (40 percent) were male.

PD age range was from 10 months to 16 years, with a mean of 8.4 years. Clinical distribution of lesions is summarized in **Table 1**. Most frequent location was perioral with 41.7 percent, followed by perioral + perinasal in 25 percent of the cases (**Figure 1**). Four patients had vulvar involvement (**Figure 2 A**) associated with perioral (**Figure 2 B**) and periocular location.

In 32 patients (66.6 percent) there was history of corticosteroid use: 21 patients (43.7 percent) used inhaled corticosteroids and 11 (22.9 percent) used topical corticosteroids (hydrocortisone, betamethasone, mometasone). In 33.4 percent of patients there was no PD triggering factor. In patients using inhaled corticosteroids, dominant lesion location was perioral (n = 13) and perioral + perinasal (n = 5).


No dominant location was found in patients using topic corticosteroids.

Four (8.3 percent) patients showed perivulvar lesions, always associated with other locations. Three of them had no history of prior corticosteroid use.

Lapse between onset of corticosteroid use and appearance of lesions ranged from 7 days to 4 years, with a mean of 2 years. In patients using inhaled corticosteroids, lesions appeared in an average period of 18 months, while in patients using topical corticosteroids the average period was 3 months. PD was treated with 0.75 percent topical metronidazole in 16 patients (33.3 percent), topical erythromycin in 15 (31.3 percent), oral erythromycin in 6 (12.5 percent), combined topical and oral erythromycin in 4 (8.3 percent), oral erythromycin with 0.75 percent topical metroni-

**TABLE 1.** LESION DISTRIBUTION.

| Lesion location                    | Patients   |
|------------------------------------|------------|
| Perioral                           | 20 (41.7%) |
| Periocular                         | 2 (4.2%)   |
| Perinasal                          | 1 (2.1%)   |
| Perioral + perinasal               | 12 (25%)   |
| Perioral + periocular              | 5 (10.4%)  |
| Perioral + perivulvar              | 3 (6.2%)   |
| Perioral + perinasal + periocular  | 4 (8.3%)   |
| Perioral + periocular + perivulvar | 1 (2.1%)   |



**Figure 1.** Perinasal and perioral lesions.

dazole in 3 (6.2 percent), oral clarithromycin in 2 (4.2 percent), topical clindamycin in 1 (2.1 percent) and pimecrolimus in 1 patient (2.1 percent). Average systemic antibiotic therapy was 3 weeks.

## Discussion

Periorificial dermatitis was first described in 1970 by Gianotti, and since then several terms have been used to refer to this disease, such as Gianotti-type perioral dermatitis, granulomatous periorificial dermatitis, and Afro-Caribbean facial eruption of the childhood.<sup>2,3</sup>

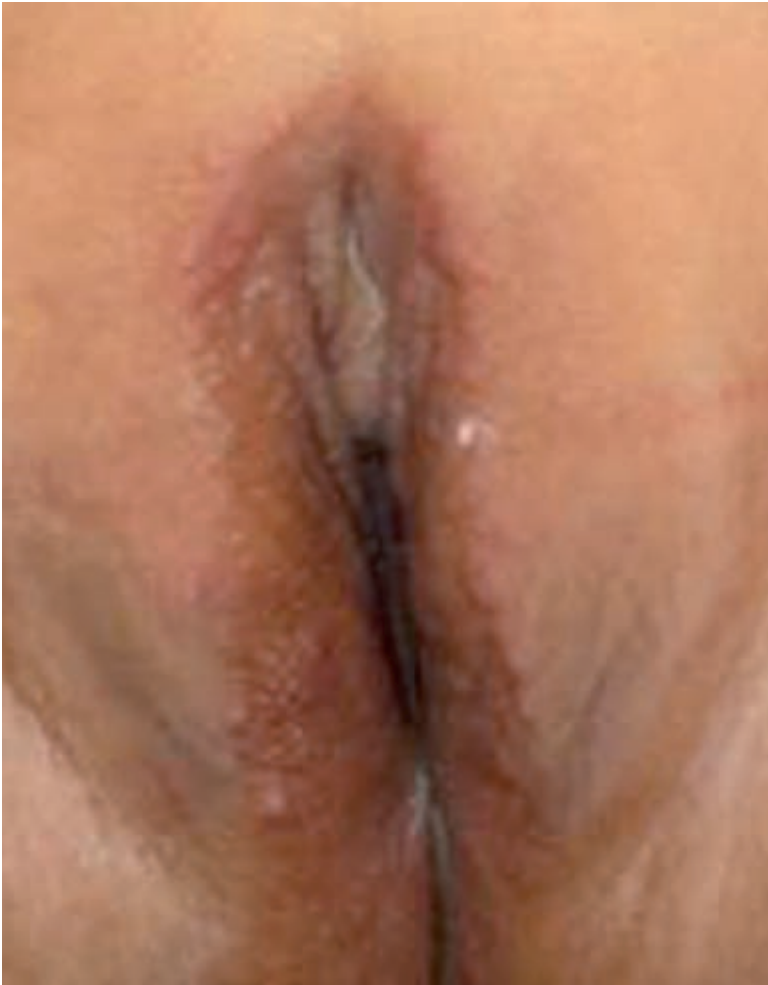

Figure 2 A. Perivulvar location.




Figure 2 B. Perioral location associated with perivulvar location.

The occurrence is higher in females, as shown in our study, where 60 percent of the patients were women. Age at presentation varies; between different reports; some studies show a higher incidence in children under 5 years.<sup>2,4</sup> In our results, mean presentation age was 8.4 years.


Clinically, PF appears with erythematous papules, papulopustules or papulovesicles, frequently with diffuse erythema, and may cause itching or burning sensation.<sup>2,5</sup> Blepharitis and conjunctivitis have occasionally been reported as associated manifestations.<sup>3</sup> Most frequent location is perioral (**Figures 3 and 4**), with a clear zone immediately around the vermilion border of the lips, but it may also involve perinasal, periorcular (**Figure 5**), and less frequently the perivulvar area.<sup>1,2</sup> Sometimes, the eruption may extend to cheeks, forehead, neck and chest, however, this is not a sign of poor disease evolution or systemic involvement.<sup>3,6</sup>

Etiopathogenesis is ill-defined; various triggering factors, both endogenous and exogenous have been suggested, of which we may point out infectious causes (*Candida*, *Demodex*), oral contraceptives, topical antibiotics, fluoride toothpaste, amalgam mercury, UVB radiation and corticosteroids (oral, topical and inhaled); the latter are the most frequent cause of periorificial dermatitis in children and adolescents.<sup>1,2,7</sup>


Topical corticosteroids of various potencies (low, medium, and high) may produce PD, as well as other adverse effects such as atrophy, telangiectasias, striae, rosacea, steroid induced acne, hypopigmentation, and hypertrichosis.<sup>8</sup> In our study, 66.6 percent of patients had history of corticosteroid use. In the group of patients using inhaled corticosteroids, lesions were mainly located on the perioral area, followed by perioral plus perinasal; this may be related to the use of nebulizing chambers or masks. We also observed that lesions appeared earlier after using topical corticosteroids.

Corticosteroids play an important role in the disease etiopathogenesis; use of topical corticosteroids may transiently relieve clinical manifestations, but these tend to relapse after medication discontinuation, being more severe in many cases.<sup>9</sup>


Diagnosis is based on clinical features and lesions distribution. Histopathologic findings are nonspecific; there is presence of lymphohistiocytic infiltrate located about hair follicles, dermal granulomatous inflammation and occasionally perifollicular abscesses.<sup>1</sup>



**Figure 3.** Perioral lesions.



**Figure 4.** Perioral lesions.



**Figure 5.** Periocular and perinatal location.

Typical appearance of periorificial dermatitis enables differentiation from other dermatosis such as rosacea, contact dermatitis, acne, seborrheic dermatitis, lip-licking cheilitis, xanthoma and papular sarcoidosis.<sup>1</sup>

In reference to treatment, in our setting the most used topical antibiotic was metronidazole (33.3 percent) followed by erythromycin (31.3 percent), and the most used oral antibiotic was erythromycin (12.5 percent).

A suggested strategy was initial use of topical metronidazole for 2 weeks and, according to the evolution, addition of oral erythromycin. Treatment duration was usually 4-6 weeks.<sup>2</sup>

Other therapeutic options with good results were topical pimecrolimus and adapalene.<sup>10-12</sup>

Although PD is a disease with good prognosis, early diagnosis and adequate treatment are necessary to improve symptoms and cosmetic involvement, and to prevent relapses.

Some studies have shown that PD occurred not only due to the use of corticosteroids, but to the device used for dispensing the drug.<sup>13</sup>

We consider important to highlight the well-documented association between use of inhaled corticosteroids in asthma management and the development of PD; thus it is very important to inform parents and patients using this type of medication, in order to optimize the effects of the drug and reduce complications.<sup>14</sup>

## References

1. Hafeez Z. Perioral dermatitis: an update. *Int J Dermatol.* 2003; 42:514-517.
2. Nguyen V, Eichenfield L. Periorificial dermatitis in children and adolescents. *J Am Acad Dermatol* 2006; 55:781-785.
3. Urbatsch AJ, Frieden I, Williams ML, Elewski BE, et al. Extrafacial and generalized granulomatous periorificial dermatitis. *Arch Dermatol* 2002; 138:1354-1358.
4. Kuflik JH, Janniger CK, Piela Z. Perioral dermatitis: an acneiform eruption. *Cutis.* 2001; 67:21-22.
5. Weber K, Thurmayr R. Critical appraisal of reports on the treatment of perioral dermatitis. *Dermatology.* 2005; 210:300-307.
6. Boeck K, Abeck D, Werfel S, Ring J. Perioral dermatitis in children- clinical presentation, pathogenesis- related factors and response to topical metronidazole. *Dermatology.* 1997; 195:235-238.
7. Guarneri F, Marini H. An unusual case of perioral dermatitis: possible pathogenic role of neurogenic inflammation. *J Eur Acad Dermatol Venereol.* 2007; 21:410-412.

8. Hengge UR, Ruizcka T, Schwartz RA, Cork MJ. Adverse effects of topical glucocorticosteroids. *J Am Acad Dermatol.* 2006; 54:1-15.
9. Manders SM, Lucky AW. Perioral dermatitis in childhood. *J Am Acad Dermatol.* 1992; 27:688-692.
10. Opiel T, Pavicic T, Kamann S, Brautigam M, et al. Pimecrolimus cream (1%) efficacy in perioral dermatitis - results of a randomized, double-blind, vehicle-controlled study in 40 patients. *J Eur Acad Dermatol Venereol.* 2007; 21:1175-1180.
11. Rodríguez-Martín M, Sáez-Rodríguez M, Carnerero-Rodríguez A, Rodríguez-García F, et al. Treatment of perioral dermatitis with topical pimecrolimus. *J Am Acad Dermatol.* 2007; 56:529-530.
12. Jansen T. Perioral dermatitis successfully treated with topical adapalene. *J Eur Acad Dermatol Venereol.* 2002; 16:175-177.
13. Dubus JC, Marguet C, Deschildre A, Mely L, et al. Local side-effects of inhaled corticosteroids in asthmatic children: influence of drug, dose, age, and device. *Allergy.* 2001; 56:944-948.
14. Poulos GA, Brodell RT. Perioral dermatitis associated with an inhaled corticosteroid. *Arch Dermatol.* 2007; 143:1460.