

Clinical patterns of pigmentary mosaicism - our experience

Gimena Castro Pérez¹, Patricia Della Giovanna², Hugo Néstor Cabrera³ and Sandra García⁴

ABSTRACT

Pigmentary mosaicisms are nevoid diseases characterized by the presence on the skin of hyper- or hypopigmented macules with particular clinical patterns. Occasionally they show association with extracutaneous defects that may alter the normal development of the affected person. We present a compilation of all the cases of pigmentary mosaicism evaluated at our Department in the past decade (Dermatol. Argent., 2011, 17(5): 375-381).

Keywords:

pigmentary mosaicism, nevoid hypermelanoses, hypomelanosis of Ito, pigmentary genes.

Submission date: 19/05/2011 | **Approval date:** 27/05/2011

Introduction

Pigmentary mosaicisms convey the existence of two cell lines with different genetic information for a given characterization in one individual. They are evidenced at cutaneous level as hyper- or hypopigmented macules distributed according to pigmentary patterns. Five such patterns have been recognized: Blaschko's lines, checkerboard, phylloid, patches with no midline demarcation and lateralized. There are cases which, besides the pigmentary manifestations, simultaneously evidence neurological and bone defects, mental retardation and particular phenotype, thus conforming actual neurocutaneous syndromes which alter the normal development of the affected individual.

¹ Dermatology Department Staff

² Chief A/C of Dermatology Department

³ Dermatology Department Consultant Professor

⁴ Chief of Dermopathology Section at Pathological Anatomy Department

Hospital Nacional Prof. Dr. Alejandro Posadas, Presidente Illia s/n and Marconi, El Palomar, Buenos Aires, Argentina

Contact: Gimena Castro Pérez, Martín Rodríguez 3789, Carapachay, Zip code 1605, Vicente López, Buenos Aires.

gimecastroperez@yahoo.com.ar

Objetivos

- To compile all the cases of pigmentary mosaicism evaluated at the Dermatology Department in the past decade.
- To determine its main demographic characteristics.
- To know its distribution according to described clinical patterns and categories.
- To determine the incidence of extracutaneous associations in the study population.

Material and methods

We used: the picture archive at the Dermatology Department; the Pathological Anatomy Department database and clinical histories of patients selected from the Hospital Nacional Alejandro Posadas Archive.

A compilation was done of the cases of pigmentary mosaicism evaluated at our Department between January 1999 and December 2009; their main demographic and clinical characteristics and their extracutaneous associations were described and relevant literature was reviewed.

Results

In this paper, we considered the following categories of pigmentary mosaicism:

1. Flat pigmentary nevus.
2. Linear pigmentary nevus.
3. Speckled pigmentary nevus.
4. Segmental pigmentary nevus.
5. Linear and whorled nevoid hypermelanosis.
6. Pigmentary mosaicism of Ito.
7. Phylloid hypomelanosis.

All clinical categories of pigmentary mosaicism evaluated were identified according to the pigmentary pattern within which they occurred.

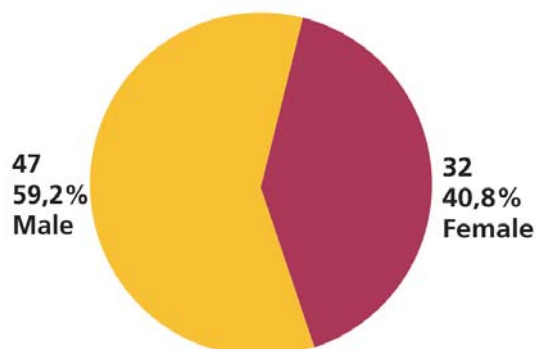
Throughout a decade, we evaluated a total of 79 patients with pigmentary disorders previously enumerated. We detected that the sex distribution was 57 males (59.2%) and 32 females (40.8%) (Graph 1).

As regards age at first consultation, 60.15% consulted before age 10 and we did not have any consultations by people over 30 (Graph 2).

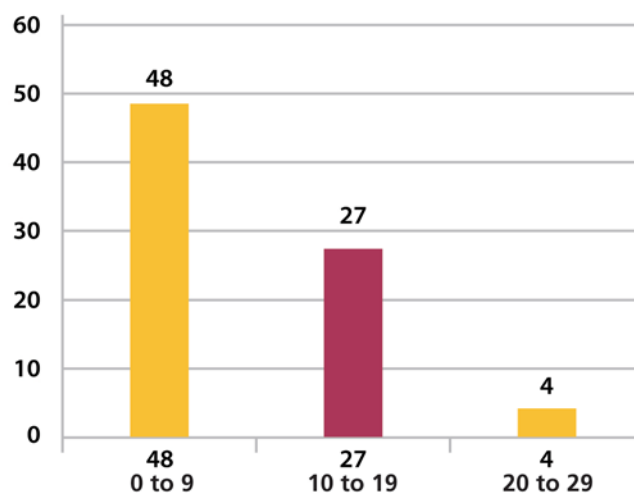
If the color of the affected skin is taken into account, we observed that hyperpigmentation was widely predominant with a total of 73 cases (92%) (including nevi pigmentosus and linear and whorled nevoid hypermelanosis) and only 6 cases were pigmentary mosaicism of Ito.

Regarding clinical categories, we were able to objectify that flat pigmentary nevus was the most frequently observed disorder in a total of 27 cases (Graph 3).

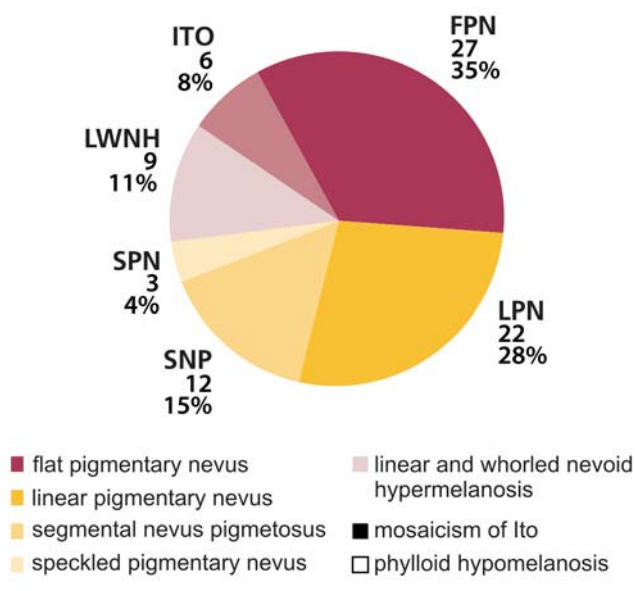
GRAPH 1: Distribution by sex



GRAPH 2: Distribution by age at first consultation. The vertical axis shows the number of patients and the horizontal axis their age



GRAPH 3: Distribution by clinical category



In our study group, the five clinical patterns described were represented as follows: in the hypopigmented forms, we found only the type 1 pattern or narrow Blaschko's lines, and among the hyperpigmented forms, the most frequently observed patterns were the narrow Blaschko's lines pattern and patches with no midline demarcation pattern (See Graphs 4.1 and 4.2)

As for extracutaneous associations, they were detected in 43.03% of patients (34 cases) and from the most to the least frequent, they were: neurological and developmental defects, followed by bone, ophthalmologic and hearing defects.

Comments

In 1993, Happle¹ posited the classification of pigmentary patterns associated to human mosaicism that we use today. He described four patterns: narrow and broad band Blaschko's lines, checkerboard arrangement, phylloid and patches with no midline demarcation. Later on, the fifth pattern was added: lateralized². Since then, a great deal of research work has attempted to explain the mechanisms underlying such clinical manifestations²⁻⁵.

The term "genetic mosaic" defines an organism consisting of two or more cell lines of different genetic or chromosomal structure originated from a genetically homogeneous zygote. This differs from genetic chimera, which consists of two or more genetically different cell lines originated from different zygotes^{2,6}.

According to the underlying etiologic mechanism, mosaicism can be classified into epigenetic and genomic⁷.

Epigenetic mosaicism is mainly due to the activity of particles called transposons and mechanisms such as Lyon's effect, responsible for X chromosome functional mosaicism.

Transposons, also known as "control elements" or "jumping genes", are particles of retroviral origin which are part of the DNA of mammals. In humans, they account for up to 42% of DNA. However, most of them are inactive. Occasionally, these "control elements" are activated during embryogenesis and by means of processes of methylation and demethylation of neighboring DNA, they induce the expression or silencing of certain genes, which gives rise to different phenotypes, among which are the linear patterns following Blaschko's lines, as occurs in some pigmentary mosaicism⁷.

Lyonization consists in the randomized, functional inactivation of one of the two X chromosomes (maternal or paternal), which make up the cells of a female zygote. Such inactivation will express equally in all the daughter cells of the cell line resulting in a mosaic with two geneti-

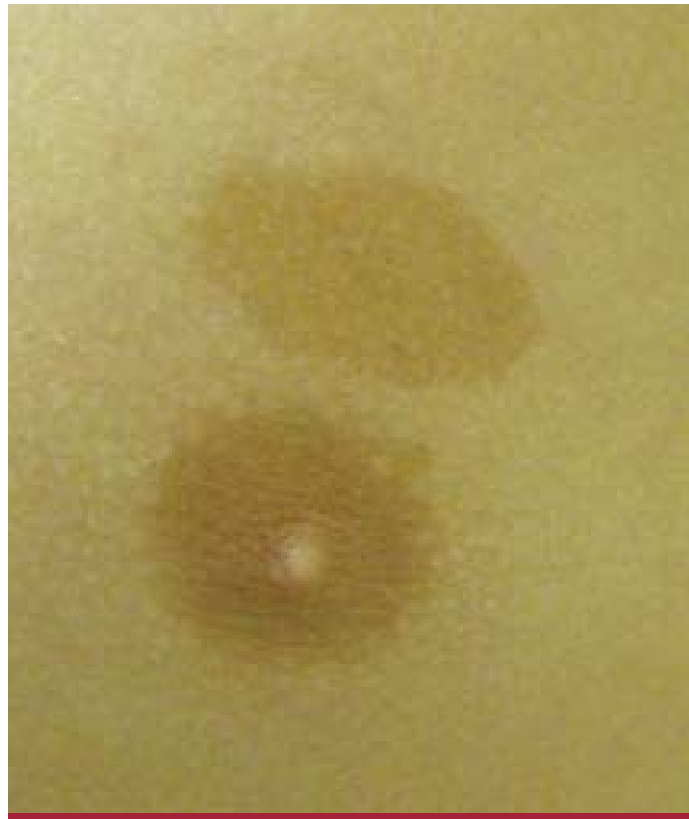

Photo 1: Flat pigmentary nevus.

cally identical but functionally different cell lines. These phenotypes will also develop skin lesions following Blaschko's lines (e.g., incontinentia pigmenti and focal dermal hypoplasia).

X chromosome functional mosaicism renders phenotypes which are transmitted from mother to daughter but they may affect male individuals of normal 46 XY karyotype, though this is due to early postzygotic mutations or to gametic mutations of the sister chromatid^{2,6}.

Genomic mosaicism is caused by somatic mutations, in which the mosaic pattern is not inherited⁷. In this case, the organism consists of two cell populations differing in their genome. If the somatic mutation affects a dominant lethal gene, its presence in a zygote leads to its death so it can only survive in mosaic state, that is, nearby normal cells. Such alteration cannot be transmitted to the next generation as these mosaicism originate from early postzygotic mutations or mutations of the chromatid of one of the gametes before fecundation. McCune-Albright and Proteus syndromes are examples of this type of disease. If the affected gene is not lethal, it may be transmitted to descendants and the phenotype will be diffuse and non-mosaic^{4,7}.

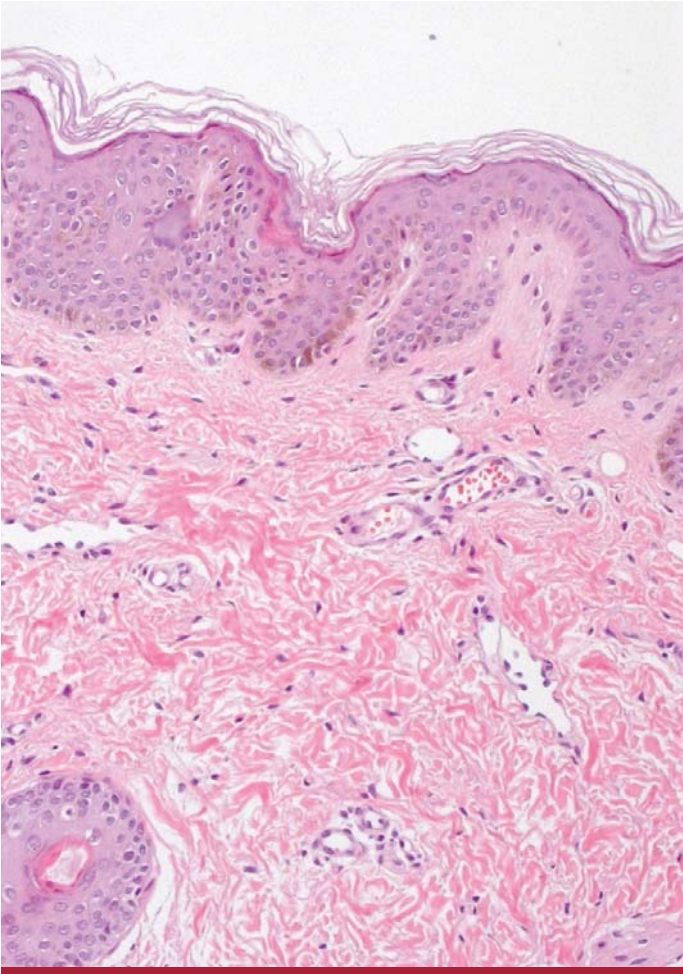


Photo 2: H&E. Increase in melanin pigment in basal layer. Note absence of pigment incontinence.

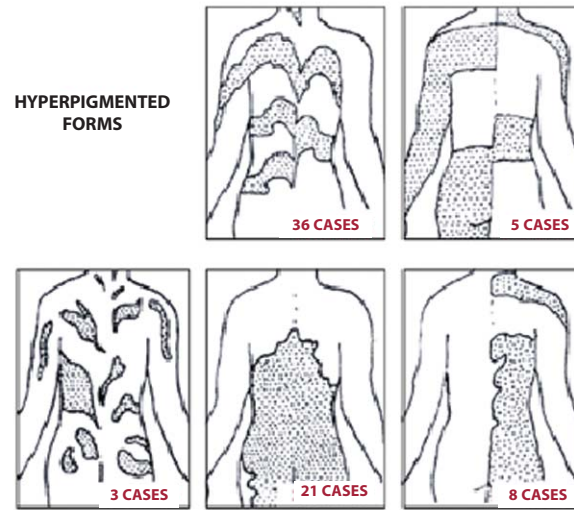
Other posited mechanisms are: genetic imprinting, para-dominant inheritance, phenotypic switching and autosomal monoallelic expression.

These alterations affect the expression of genes called "pigmentary genes". There are about a hundred pigmentary genes involved in melanogenesis, melanocytic expression, melanocyte development or migration, melanosome biogenesis, melanosome transfer and growth factors and receptors⁴.

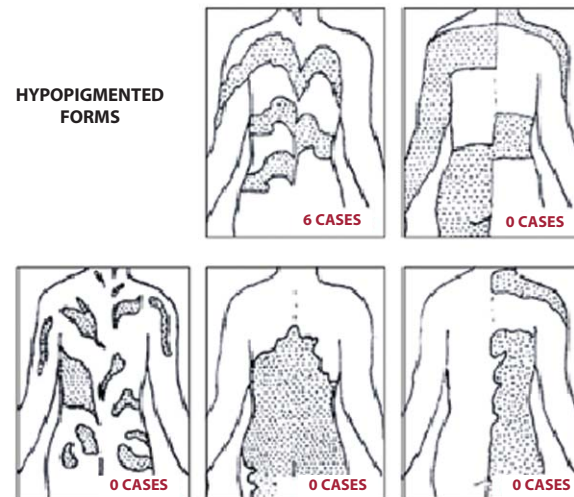
It can be therefore deduced that there are multiple genetic mechanisms responsible for the development of a variety of neurocutaneous or purely cutaneous syndromes called pigmentary mosaicisms.

Pigmentary nevi are hyperpigmented macules due to a quantitative variation in the melanin pigment but not in the number of melanocytes⁸. Clinically, they are identified as generally uniform brownish macules with net, soft, irregular limits. They appear at birth and are not modified throughout life. Within this category, there are flat, line-

GRAPH 4.1. Distribution of hyperpigmented forms according to the different clinical patterns [Happle et al, Hautarzt 2004]



GRAPH 4.2. Distribution of hypopigmented forms according to the different clinical patterns [Happle et al, Hautarzt 2004]



ar, speckled and segmental pigmentary nevi. They may all manifest in isolation or as part of different syndromes, such as Albright, Turner, neurofibromatosis, tuberous sclerosis, etc. To carry out our study, we have excluded all those pigmentary nevi which are part of specific syndromes, such as the ones just mentioned.

We have found a total of 64 cases of pigmentary nevi (81% of the total of mosaicisms studied) among which the flat pigmentary nevus was the most usual with 27 cases (Photo 1), followed in order of frequency by linear (22 cases), segmental (12 cases) and finally speckled (3 cases).

Of these 64 cases, 30 (46.8%) presented some associated extracutaneous alteration.

Histopathology showed that the studied cases evidenced findings typical of pigmentary nevi: increase of melanin pigment at the basal layer and discrete elongation of rete ridges⁸.

Linear and whorled nevoid hypermelanosis (LWNH) was described by Kalter in 1988⁹ as a sporadic pigmentary disorder which manifests in the first few weeks after birth with whorled hyperpigmented macules following Blaschko's lines, sparing mucosa, palms and soles. It appears on areas where there were no preceding pustular or verrucous lesions (so *incontinentia pigmenti* may be excluded); it does not show any predilection for sex and it is occasionally accompanied by extracutaneous findings affecting mainly the nervous and musculoskeletal systems. Histologic tests of the hyperpigmented skin areas evidence basal hyperpigmentation with no increase in the number of melanocytes when there is no pigmentary incontinence (Photo 2). Among the chromosomal anomalies described in association with this entity are anomalies of chromosomes 7,14,18 and X¹⁰⁻¹⁵.

In our research we have found a total of 9 LWNH cases but we have not found any associated extracutaneous alterations in any of them (Photo 3).

The term hypomelanosis of Ito refers to a set of neurocutaneous phenotypes in which there are hypopigmented macules following Blaschko's lines and which may be associated or not with neurological defects, malformations and chromosomal anomalies. This disease tends to evidence at birth by means of multiple symmetric bilateral hypopigmented macules affecting the trunk and limbs. Among the possible associated alterations are hypertrichosis, hyperhidrosis, mental retardation, microcephaly, hypotony, ataxia, convulsions, eye defects, hearing loss, short stature, facial and limb asymmetry, scoliosis, polydactyly, etc. Reports of these disorders range from 75 to 100% of cases¹⁶. According to the literature consulted, the cytogenetic study of published cases shows karyotype alterations and involves different chromosomes: X,^{12,18} with trisomies and triploidies^{4,17,18}. Such alterations affect the expression of the so-called "pigmentary genes".

Thus, it is nowadays preferable to refer to this disease as pigmentary mosaicism of Ito as it is considered a spectrum of entities with varied extracutaneous defects which have a cutaneous pigmentary pattern in common^{4,10,17} and respond to certain chromosomal anomalies involving different pigmentary genes⁴.

We have evaluated 6 cases of pigmentary mosaicisms of Ito and we have observed that four of them evidenced developmental delay and peculiar facies (fish face) (Photo 4).

Phylloid hypomelanosis is considered a neurocutaneous syndrome manifesting through a combination of multiple hypopigmented macules among which are: absence of corpus callosum, neurosensorial deafness, iris coloboma,

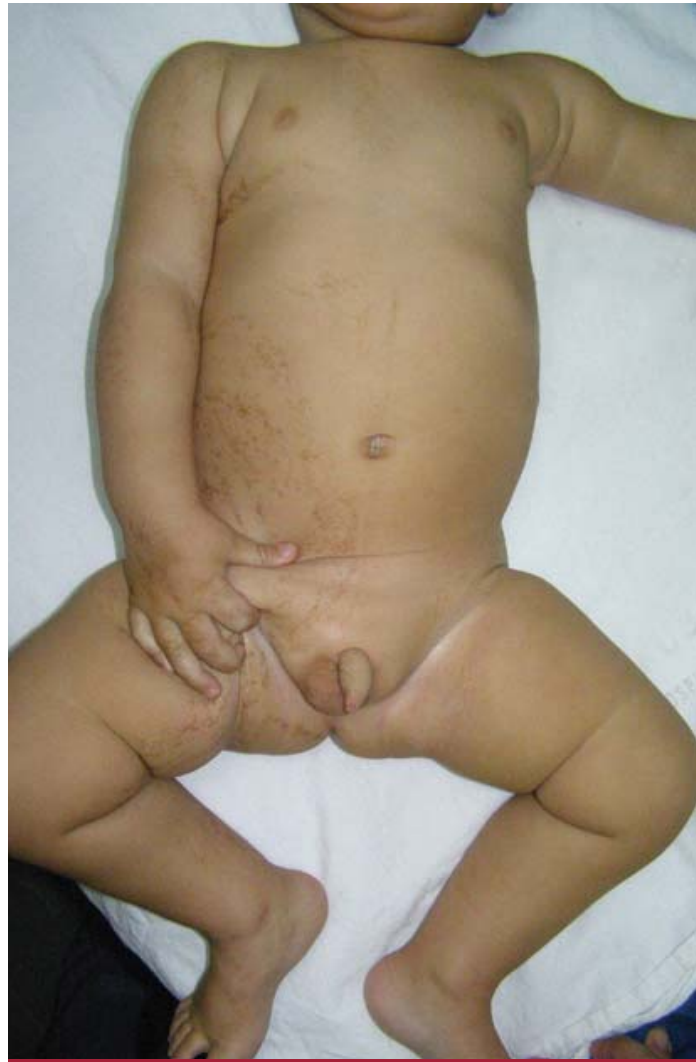

Photo 3: Linear and whorled nevoid hypermelanosis.

rhino-facial defects, brachydactyly and clinodactyly. Only 8 cases of this entity were reported worldwide until 2009. In all of them girls were affected and cytogenetic studies showed genomic mosaicisms with chromosome 13 trisomy^{7,19}, which is why some authors consider it a new nosological entity different from hypomelanosis of Ito and Pattau's disease (non-mosaic 13 trisomy), and posit that the appearance of hypochromic macules with a phylloid pattern associated to extracutaneous defects indicate chromosome 13 mosaicism^{7,19}.

There were no cases with this disease among the patients included in our ten-year study.

We carried out an analysis of the distribution of our cases according to the cutaneous pigmentary patterns described by Happle¹ and the presence of hypo- and hyperpigmentation. We have found that Blaschko's lines pattern was the most frequent in hyperpigmented lesions (28 narrow




Photo 4: Peculiar facies in a patient with hypomelanosis of Ito.




Photo 5: Checkerboard pattern.

band cases and 8 broad band cases) and the only one present in hypopigmented lesions (6 cases with mosaicism of Ito). The second in order of frequency was the one of patches with no midline demarcation (21 cases), followed by 8 lateralized pattern cases, 5 checkerboard cases (Photo 5) and 3 phylloid pattern cases.

Extracutaneous manifestations were present in 34 of the patients studied (43.03%) with a prevalence of 41.09% in hyperpigmented forms and 66.6% in hypopigmented forms (4 of 6 cases).

Among the most frequently observed alterations were neurological with epilepsy and developmental delay, followed by strabismus, bone defects and hearing loss.

Conclusions

- We evaluated 79 patients with pigmentary mosaicisms over a period of 10 years.
- We found males were more frequently affected.
- 60.15% was evaluated for the first time before 10 years of age.
- Hyperpigmented forms prevailed over hypopigmented ones, with 73 of 79 cases, that is, a ratio of 8.1 to 1.
- The most frequent clinical form of pigmentary mosaicism was the flat pigmentary nevus.
- The most frequently seen cutaneous pigmentary pattern was type 1 or Blaschko's lines in both hypo- and hyperpigmented forms.
- 43.03% of the patients studied evidenced extracutaneous manifestations.
- Extracutaneous involvement was more frequent in hypopigmented forms.
- Developmental disorders and convulsions were the most frequent extracutaneous defects.

Bibliography

1. Happle R. Pigmentary patterns associated with human mosaicism: a proposed classification, *Eur. J. Dermatol.*, 1993, 3: 170-174.
2. Happle R. Mosaicism in human skin: understanding the patterns and mechanisms, *Arch. Dermatol.*, 1993, 129: 1460-1469.
3. Happle R. Monoallelic expression on autosomes may explain an unusual heritable form of pigmentary mosaicism: a historical case revisited, *Clin. Exp. Dermatol.*, 2009, 34: 834-837.
4. Taibjee S.M., Bennett D.C. and Moss C. Abnormal pigmentation in hypomelanosis of Ito and pigmentary mosaicism: the role of pigmentary genes, *Br. J. Dermatol.*, 2004, 151: 269-282.
5. Horn D., Happle R., Neitzel H. and Jürgen K. Pigmentary mosaicism of the hyperpigmented type in two half-brothers, *Am. J. Med. Genet.*, 2002, 112: 65-69.

6. Pueyo de Casabé S., Massimo J.A., Boente M.C. Mosaicismos cutáneos, *Dermatología infantil en la clínica pediátrica*, Editorial Artes Gráficas Buschi, Buenos Aires, 1999.
7. Happle R. Muster auf der Haut: Neues zu entwicklungsbiologischen und genetischen Ursachen, *Hautarzt*, 2004, 55: 960-968.
8. Cabrera H.N., García S.M. Nevos epidérmicos en Cabrera H.N. y García S.M., *Nevos*, Editorial Actualizaciones Médicas, Buenos Aires, 1998.
9. Kalter D.C., Griffiths W.A., Atherton D.J. Linear and whorled nevoid hypermelanosis, *J. Am. Acad. Dermatol.*, 1988, 19: 1037-1044.
10. Di Lernia V. Linear and Whorled hypermelanosis, *Pediatr. Dermatol.*, 2007, 24: 205-210.
11. Megarbane A., Vabres P., Slaba S., Smahi A. *et al.* Linear and whorled nevoid hypermelanosis with bilateral giant cerebral aneurysms, *Am. J. Med. Genet.*, 2002, 112: 95-98.
12. Komine M., Hino M., Shiina M., Kanazawa I. *et al.* Linear and whorled nevoid hypermelanosis. A case with systemic involvement and trisomy of 18 mosaicism, *Br. J. Dermatol.*, 2002, 146: 500-502.
13. Yan L.U., Wen-Yuan Z.H.U. Linear and whorled nevoid hypermelanosis complicated with inflammatory linear verrucous epidermal nevus and ichthyosis vulgaris, *J. Dermatol.*, 2007, 34: 765-768.
14. Llamas-Velasco M., Eugren C., Arranz E., Renedo M. *et al.* Linear and whorled nevoid hypermelanosis and axenfeld-riege anomaly: a novel association, *Acta Derm. Venereol.*, 2009, 90: 428-429.
15. Vergheze S., Newlin A., Miller M., Burton B.K. Mosaic trisomy 7 in a patient with pigmentary abnormalities, *Am. J. Med. Genet.*, 1999, 87: 371-374.
16. Ruiz-Maldonado R., Toussaint S., Tamayo L., Laterza A., *et al.* Hypomelanosis of Ito: Diagnostic criteria and report of 41 cases, *Pediatr. Dermatol.*, 1992, 9: 1-10.
17. Küster W., König A. Hypomelanosis of Ito: No entity, but a cutaneous sign of mosaicism, *Am. J. Med. Genet.*, 1999, 85: 346-350.
18. Gupta S., Shah S., McGaw A., Mercado T. *et al.* Trisomy 2 mosaicism in hypomelanosis of Ito, *Am. J. Med. Genet.*, 2007, 143A: 2466-2468.
19. Ribeiro Noce T., Monteiro de Pina-Neto J., Happle R. Phylloid Pattern of Pigmentary disturbance in a case of complex mosaicism, *Am. J. Med. Genet.*, 2001, 98: 145-147.