

Retrospective study of Hallopeau-type pemphigus vegetans throughout a 20-year period. Review of the literature

Graciela Pizzariello¹, Liliana Olivares², Olga Forero³, Gisela D' Atri⁴, Patricia Fernández Pardal⁵ and Javier Anaya⁶

ABSTRACT

Hallopeau-type pemphigus vegetans is a rare form of pemphigus characterized by the development of vegetating lesions located mainly on flexural areas. A retrospective study was carried out of patients with diagnosis of pemphigus admitted at our Department (1988-2007). The three cases found to be Hallopeau-type pemphigus vegetans are described and a review of the literature is performed (Dermatol. Argent., 2011, 17(4): 294-300).

Keywords:

pemphigus vegetans, Hallopeau, Neumann.

Submission date: 22/03/2011 | **Approval date:** 18/04/2011

Introduction

Pemphigus vegetans (PV) is considered by many authors to be a rare variant of pemphigus vulgaris¹⁻⁴ and is characterized by vegetating lesions, acantholysis in histopathology and IgG deposition and/or complement with honeycomb pattern in immunofluorescence. It is an infrequent disease whose exact prevalence is unknown.

PV was referred to as a variant of pemphigus vulgaris by Neumann in 1876⁵, and 13 years later, Hallopeau described at the First International Congress of Dermatology and Syphilography, in Paris, a different variant of pemphigus vegetans characterized by the presence of pustules, which bears his name⁶.

These two forms of PV differ in their clinical presentation, course and prognosis. By virtue of the therapeutic implications that this entails, we highlight the relevance of differentiation between both variants.

¹ Chairman of Medical Division

² Chief of Dermatology Department

³ Medical Staff

⁴ Former Instructor of Residents

⁵ Chief of Residents

⁶ Dermopathologist

Dermatology Department, Hospital Muñiz, Ciudad Autónoma de Buenos Aires, República Argentina.
Contact: Graciela Pizzariello, Montevideo 471, 5ª A Zip 1019, Ciudad Autónoma de Buenos Aires.
gracielopizzariello@hotmail.com

Objectives

- To estimate the prevalence of Hallopeau-type pemphigus vegetans in the overall number of pemphigus cases and the relative frequency of each clinical manifestation of the disease.
- To characterize its presentation, response to treatment and course.

Material and methods

A review was carried out of the patients who were hospitalized at our Department between January 1998 and December 2007 who were diagnosed with pemphigus through clinical, histopathological evaluation and immunofluorescence (the latter in most of the cases).

Results

A total of 203 patients were analyzed (Graph 1). Pemphigus vulgaris is the most frequent variant - 70.5% of cases. The second most frequent variant is seborrheic pemphigus (15%), pemphigus foliaceus (6%), pemphigus herpetiformis (6%), IgA pemphigus (0.5%) and paraneoplastic pemphigus (0.5%). Hallopeau-type pemphigus vegetans constitutes 1.5% of the patients population studied and corresponds to the three cases described below.

Clinical cases

Case 1

45-year old female, without relevant pathological antecedents, who consulted at our Department because of lesions on the scalp, lip commissures and axillae after a one-year course.

Physical examination: on scalp, we observed a large oval raised lesion, 5 x 7 cm in diameter, pink-grayish in color and with irregular surface, with isolated erosions covered by small yellowish crusts (Photo 1). It was soft, with a non-infiltrated base and painless. On the axillary area, there were many papillomatous agminated formations with a purulent secretion and fetid odor (Photo 2). Such lesions were also present on lip commissures (Photo 3). On labial semi-mucosa, there were erosions mostly covered by hematic and "honey-colored" yellow crusts. The rest of the skin was unaffected, Nikolsky sign was negative and her general condition was good.

Complementary tests: laboratory: WBC count 6,000 cell/mm³ (Eo 10%, 600 cell/mm³), the rest was unremarkable.

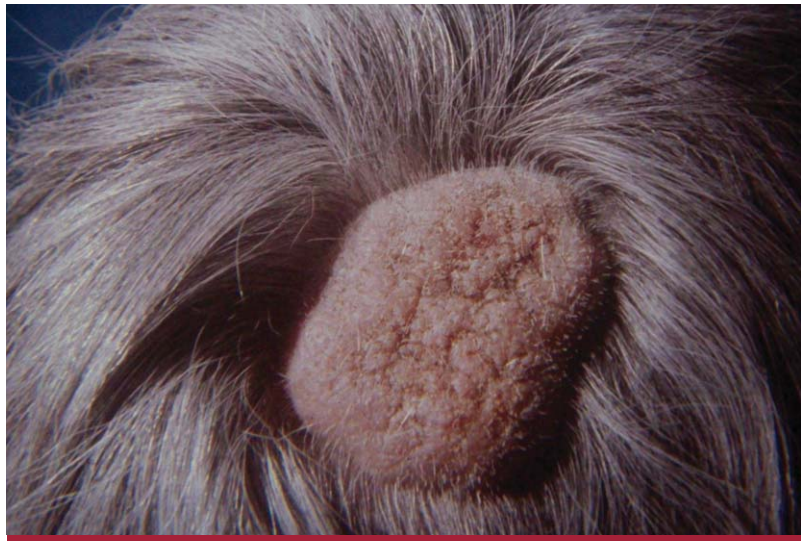

Photo 1: Scalp. Vegetating lesion.

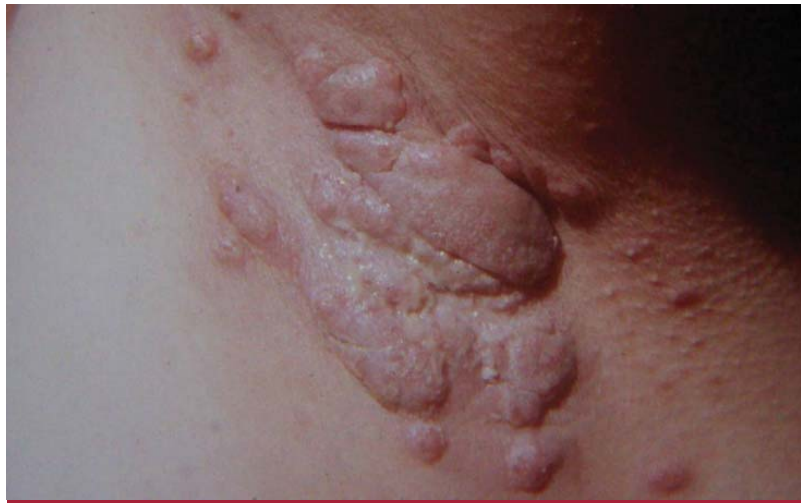

Photo 2: Axilla. Vegetating lesion.



Photo 3: Papillomatous, agminated formations on lip commissures. Erosions on labial semi-mucosa.

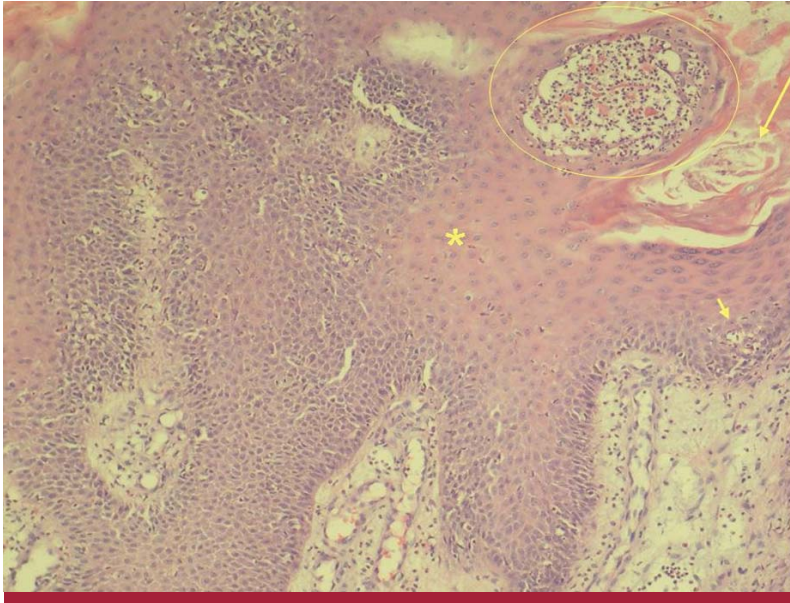


Photo 4: Skin histopathology. Long arrow: hyperkeratosis. Asterisk: acanthosis. Circle: intraepidermal accumulation of eosinophils. Short arrow: suprabasilar cleavage with acantholysis.

TABLE 1: Complementary examinations

	Variants of Pemphigus vegetans	
	Hallopeau	Neumann
Cytodiagnosis	Acantholytic cells	
Histopathology	Similar. Acanthopapillomatosis, suprabasilar bullae, acantholysis, microabscesses of intraepidermal eosinophils ²⁰ (more numerous and larger in Hallopeau-type variant ^{7,11,17}). Eosinophilic spongiosis. Inflammatory infiltrate on dermis with lymphocytes, neutrophils and eosinophils.	
Immunofluorescence	IgG and C3 deposition with honeycomb pattern. In some cases, there is also IgA ¹⁷ .	
Elisa	Desmoglein3 ²⁷ .	
Immunoprecipitation	130 kD ¹¹	130 and 85 kD ¹¹

kable. Cytodiagnosis of vegetating lesions and erosions on labial semi-mucosa: acantholytic cells. Histopathological skin examination: epidermal hyperkeratosis, marked acanthosis and microabscesses consisting mainly of eosinophils alternating with suprabasilar cleavage with acantholysis (Photo 4). Immunofluorescence was not performed because of lack of availability.

Diagnosis: Hallopeau-type pemphigus vegetans.

Treatment: methylprednisone 0.5 mg/kg/day orally; dapsone 100 mg/kg/day orally (steroid sparing); ampicillin 1g every 6 hours EV (for 14 days).

Course: slow and favorable, showing remission during two years of follow-up.

Case 2

40-year-old male, with asthma and epilepsy antecedents, under treatment with diphenylhydantoin, who was first seen at our Department in 1994 due to exophytic, pruriginous lesions on axillae and inguinoscrotal and intergluteal folds, after a course of several months.

Physical examination: on the axillae, papules and reddish-purple plaques which converged forming vegetating-like lesions. These lesions were also visible on the inguinoscrotal region and intergluteal fold, where they presented an erosive, oozing, smelly surface (Photo 5). There were erosions on labial semi-mucosa. He did not evidence any other cutaneous manifestation, Nikolsky sign was negative and, like in the previous case, the patient's general condition was good.

Complementary examinations: laboratory: WBC count 10500 cell/mm³ (Eo 5%, 525 cell/mm³, the rest was unremarkable). Cytodiagnosis of vegetating lesions and erosions on oral semi-mucosa: flaps of acantholytic cells.

Histopathological skin examination: epidermal acanthopapillomatosis and collections inside it formed by eosinophils and acantholytic cells. Indirect immunofluorescence: IgG with an interkeratinocyte pattern, titer 1/40.

Diagnosis: Hallopeau-type pemphigus vegetans.

Treatment: methylprednisone 0.5 mg/kg/day orally, dapsone 100 mg/kg/day orally, ciprofloxacin 500 mg every 12 hours and metronidazole 500 mg every 8 hours (for 14 days).

Course: complete remission of dermatosis for 5 years after which he relapsed with the same places previously affected. These lesions also evolved favorably when treatment was resumed.

Case 3

84-year-old male, without known pathological antecedents, who, 14 months before consultation (2006), had recurrent outbreaks of pustules on large folds area which progressed into vegetating lesions.

Physical examination: on axillary region, voluminous vegetating lesions, of irregular surface, with deep grooves in which purulent, fetid material collected and alternated with pustule-strewn plaques (Photo 6). Some less significant lesions could be observed on left submammary fold. On the inguinoscrotal region, the lesions were of a considerable size and adopted a cerebriform aspect (Photo 7). Like in the previous cases, there were no other cutaneous lesions, the mucosal membranes were unaffected, Nikolsky sign was negative and the dermatosis did not alter the general condition.

Complementary examinations: laboratory: Hb 9.4 g/dl, Hto 27% (ferrokinetic profile: chronic disorder anaemia); WBC count 6,700 (eosinophils 15%), VSG 71 mm/1st

hour, albumin 3.2 g/dl. The rest was unremarkable. Cytodiagnosis: flaps of acantholytic cells. Histopathological skin examination 40 X: epidermal parakeratosis, acanthosis, irregular lengthening of rete ridges and an intraepidermal pustule. 100X: it was observed that this pustule contained some neutrophils, numerous eosinophils and isolated acantholytic cells. On the epithelium, eosinophilic spongiosis was observed and the underlying dermis evidenced moderate inflammatory infiltrate consisting of lymphocytes and eosinophils. IFD: IgG deposition and interkeratinocyte C3.

Diagnosis: Hallopeau-type pemphigus vegetans.

Treatment: methylprednisone 1 mg/kg/day, ciprofloxacin 500 mg every 12 hours, clindamycin 600 mg every 6 hours EV.

Course: improvement of dermatosis, but the patient presented sepsis from the cutaneous lesions. The initiation of immunosuppressive treatment was suggested but the patients did not return for controls.

Discussion and literature review

Pemphigus vegetans is predominant in adults between 40 and 50 years old but it may occur in other age groups, including children⁷ and it might be a little more frequent in females². It is an autoimmune disease involving antibodies directed against desmosomal proteins present in stratified squamous epitheliums. Such antibodies exhibit pathogenic activity. Anti-desmoglein 3 antibodies (130 kD) are usually produced in both variants. However, in the Neumann type, an 85 kD protein not present in the Hallopeau type, is also detected by immunoprecipitation. In some patients, anti-desmoglein 1 and anti-periplakin⁸ and desmocollin 1 and 2⁹ antibodies have also been detected. Even if the antigen of pemphigus vegetans and classic pemphigus vulgaris is the same (130 kD desmoglein 3)¹⁰, it is posited that in the former, different subclasses of IgG would be produced (IgG 2 and 4, whereas IgG 1 and 4 are produced in pemphigus vulgaris), capable of strongly activating the complement system. This could explain the greater affluence of neutrophils and mainly of eosinophils which occurs in vegetating lesions¹¹⁻¹². Notwithstanding this, there are isolated PV cases with IgG 1 and 4¹³.

There are drug-induced cases, among which we can mention the angiotensin converting enzyme (captopril¹², enalapril¹⁴) and penicillamine¹⁰. It has even been suggested that a patient might have developed pemphigus vegetans as a consequence of intranasal heroin abuse¹⁰. The chemical structures of both captopril and penicillamine are made up of highly reactive sulfhydryl groups which could bind to pemphigus antigens and generate acantholysis. Heroin could act as another ligand of these antigens¹⁰. In the case of enalapril, its relationship with pemphigus induction is not very clear-cut¹⁴.

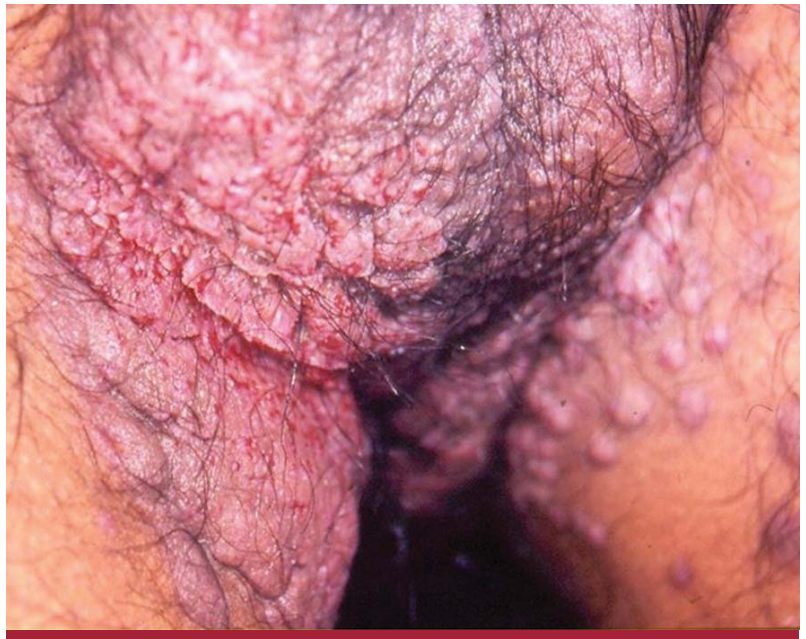

Photo 5: Inguinoscrotal and intergluteal fold. Vegetating lesions with erosive, oozing surface.

A further case of pemphigus vegetans (confirmed by histology and immunofluorescence) has been described over a skin graft¹⁵. The assumed physiopathogenic mechanism is that the injury produced by surgery would expose antigens normally hidden from the immune system thus triggering a secondary immune response with the development of antibodies capable of inducing the lesions¹⁵. This phenomenon, also called epitope spreading, has already been described for other dermatoses such as bullous pemphigoid¹⁶ and mucosal pemphigoid¹⁷⁻¹⁸.

Clinical manifestations

Hallopeau-type variant: it begins with outbreaks of pustules which become vegetating plaques¹⁹⁻²² located mainly on flexural areas²³. Oral cavity affectation is frequent for this clinical form; two of the three cases described evidenced this manifestation. Oral involvement is referred to in the literature in 92% of pemphigus vegetans patients². It may cause papillomatous lesions on commissures, vermilion lip¹⁹ and cerebriform tongue^{7,24-25} or scrotum²⁶. There are cases exclusively circumscribed to the lips and oral mucosa, scalp²⁷, and others which involve only the foot^{22,27}. Some atypical forms have also been reported to affect fingers and toes mimicking acrodermatitis continua²¹, or to present verrucous acral lesions (including 20-nail verrucous paronychia with nail dystrophy)¹⁹. The cases which mimic acrodermatitis continua can be really severe and



Photo 6: Axillary region. Left: voluminous vegetating lesions. Right: pustule-strewn plaques.

lead to alterations in the phalanges and loss of nails²¹. Besides, this clinical form may be the first manifestation of the disease after which folds and oral mucosa involvement may develop some months later²¹. Furthermore, it is interesting to note that these patients may present HLA related in turn with pustular psoriasis²¹.

The clinical condition may turn to be very florid and the vegetating lesions may develop a considerably large size. Nikolsky sign tends to be negative, as was observed in the cases reported. There is no alteration of the general condition or inner body parts^{1-2,14}.

Neumann variant: it occurs within the context of a classic pemphigus vulgaris³. It starts with flaccid bullae which slough giving way to erosions some of which adopt a vegetating aspect¹¹. The bullae may be found mainly on folds, where friction and maceration favor their development. However, they may occur in other places such as scalp, trunk²⁸, acral areas mimicking common warts and causing paronychia with onychodystrophy²⁹ (onycholysis, onychomadesis, subungual hyperkeratosis and trachyonychia, among others)^{19,29}. The classic involvement of folds may be absent in these atypical cases.

Exceptionally, there might be cases in which the esophagus is affected in a similar way to pemphigus vulgaris and there is significant dysphagia. In these cases, endoscopy reveals erosions and whitish plaques surrounded by a reddish halo^{24,30}, and histology shows rounded epithelial cells and infiltrate rich in eosinophils³⁰. There might occasionally be acantholytic cells³⁰. Immunofluorescence evidences intercellular IgG deposition²⁴ and Nikolsky sign tends to be positive.

To sum up, it is obvious that there is an overlapping of clinical manifestations between both forms. The vegetating

lesions, then, originate from bullae which become eroded (Neumann) or from pustules which gradually turn into hypertrophic and exophytic lesions^{7,14,19}. In the former, however, the lesions alternate with flaccid bullae and erosions and the general condition of the patient and their inner body parts tend to be altered.

In both variants, the lesions may present superinfection by bacteria and/or candida (as is the case for the three patients reported).

The presence of eosinophilia in the blood count is usual in both variants.

Diagnosis: it is performed on the basis of clinical, histopathological and immunofluorescence findings (Table 1).

PV and neoplasias: the incidence of neoplasias in patients with pemphigus is much higher than in the general population¹⁴ and constitutes between 5 to 12% of the total number of pemphigus cases²⁰. Neoplasias may precede, be concomitant with or appear after pemphigus. In most cases, neoplasia is usually diagnosed before the appearance of dermatosis. If pemphigus vegetans is itself a rare disease, its coexistence with neoplasia is even rarer. There are 5 reported cases of PV and neoplasia in the literature (2 lung neoplasias, a lymphosarcoma, a gastric carcinoma and a case of colon cancer) and in one of them there is remission of the lesions when the tumor is removed³¹. It should be taken into account that paraneoplastic pemphigus may present vegetating-type lesions within their clinical polymorphism³²⁻³³.

PV and HIV: there are various cases of patients with HIV and autoimmune bullous diseases (pemphigus vulgaris, herpetiform pemphigus, pemphigus vegetans^{25,34} and bullous pemphigoid). Whether there is a real association or they are fortuitous cases is unknown. However, antibo-

dies with pathogenic capability²⁵ could develop within the usual polyclonal hypergammaglobulinemia in prone patients. This kind of response would occur at the early stages of HIV infection due to the clonal expansion of B cells related to cellular immunity depression²⁵. In spite of this, as immunodepression progresses, both responses decrease dermatoses improve³⁴.

Differential diagnosis: condyloma accuminata, pemphigoid vegetans³⁵, benign familial pemphigus (Hailey-Hailey disease). In atypical location cases, squamous cell carcinoma, chromomycosis, hypertrophic lichen and pyoderma gangrenosum vegetans, among others.

Course: outbreaks and remissions. Hallopeau-type has a benign course^{7,10,14} (the second case reported corresponds to a patient who is still being controlled after 13-year follow-up). It has a good therapeutic response to low doses of steroids and prolonged remissions^{11,15,20}. In contrast, the Neumann variant is associated to greater skin and general condition involvement. Thus, it requires a more aggressive treatment to control the disease^{3,10-11,13-15,19}. However, its prognosis would be slightly more favorable than classic pemphigus vulgaris².

Treatment

This being an infrequent disease, it is difficult to carry out controlled, randomized trials. Publications consist in series or isolated cases. Systemic steroids are the treatment of choice for most authors⁷. The patients who have the Hallopeau-type variant require low doses, whereas the ones with the Neumann-type one need higher doses². Corticoids usually improve the lesions and are capable of inducing remission, but the disease tends to recur when their doses are lowered or they are discontinued^{7,19,27,29,36}. In other cases, the vegetating lesions are refractory to such treatment³⁶. The drugs which have been used associated to steroids as adjuvants with a good response include dapsone^{3,14,19,34,37}, immunosuppressive drugs (azathioprine^{14,19,21,29}, cyclophosphamide^{19,29}, cyclosporine^{19,21,30}, mycophenolate mofetil^{19,27}) and retinoids (etretinate^{36,38}, acitretin¹⁵). Dapsone inhibits the chemotaxis of polymorphonuclears. Retinoids reduce cell proliferation and have immunomodulatory and antiinflammatory effects, though they are not very well clear-cut. Other treatments to consider include intralesional corticoids and metotrexato¹⁹. Sawai et al describe a case of pemphigus vegetans with esophageal involvement which was successfully treated with minocycline and nicotinamide without association with steroids²⁴.

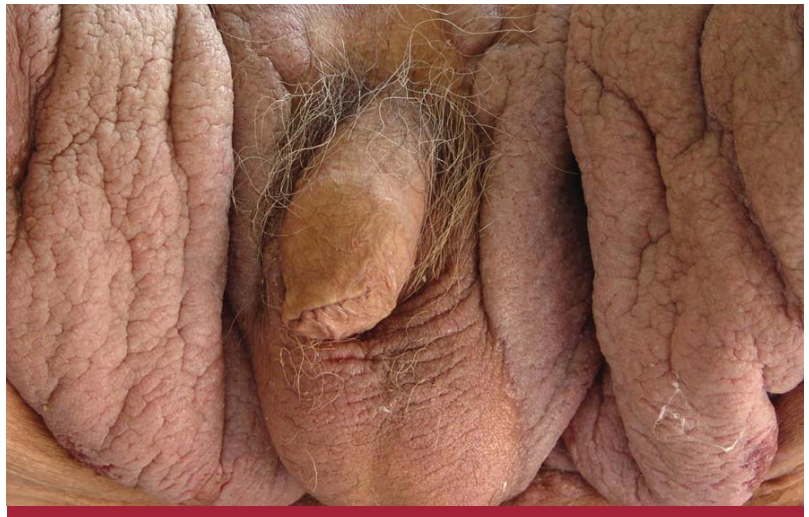


Photo 7: Inguinal region. Vegetating lesions of cerebriform aspect.

Conclusion

Hallopeau-type pemphigus vegetans represents only 1.5% of all pemphigus cases at Hospital F. J. Muñoz, which coincides with international literature publications (between 1 to 5% of all pemphigus cases)^{7,11,19}. It presents benign biological behavior, it does not require high doses of steroids and it is controlled with dapsone as adjuvant therapy.

Even if pemphigus vegetans is very rare, very important to differentiate both variants, Hallopeau-type and Neumann-type due to the prognostic and therapeutic implications that such differentiation entails.

Bibliography

1. Fariña M.C., Pique E., Olivares M., Espinel J. *et al.* Pénfigo vegetante de Hallopeau: dos formas clínicas diferentes, *Med. Cut. I.L.A.*, 1995, 23: 253-257.
2. Ahmed A.R., Blose D.A. Pemphigus vegetans. Neumann type and Hallopeau type, *Int. J. Dermatol.*, 1984, 23: 135-141.
3. Aldama A.B., Gorostiaga G., Rivelli V., Garrigoza O., *et al.* Pénfigo vegetante: dos casos con respuesta favorable al tratamiento, *Act. Terap. Dermatol.*, 2004, 27: 202-205.
4. Micali G., Musumeci M.L., Nasca M.R. Epidemiologic analysis and clinical course of 84 consecutive cases of pemphigus in eastern Sicily, *Int. J. Dermatol.*, 1998, 37: 197-200.
5. Neumann I. *Vierteljahresschrift fuer Dermatologie and Syphilis, Arch. Dermatol. Syphil.*, 1876, 3: 444-447.

6. Hallopeau H. Congres Internaional de Dermatologie et de Syphiligraphie Tenu a Paris (1^o Session), Paris, G. Masson, 1889, 344-362.
7. Markopoulos A.K., Antoniadis D.Z., Zaraboukas T. Pemphigus vegetans of the oral cavity, *Int. J. Dermatol.*, 2006, 45: 425-428.
8. Cozzani E., Christana K., Mastrogiacono A., Rampini P. *et al.* Pemphigus vegetans Neumann type with anti-desmoglein and anti-periplakin autoantibodies, *Eur. J. Dermatol.*, 2007, 17: 530-533.
9. Hashimoto K., Hashimoto T., Higashiyama M., Nishikawa T. *et al.* Detection of anti-desmocollins I and II autoantibodies in two cases of Hallopeau type pemphigus vegetans by immunoblot analysis, *J. Dermatol. Sci.*, 1994, 7: 100-106.
10. Downie J.B., Dicostanzo D.P., Cohen S.R. Pemphigus vegetans-Neumann variant associated with intranasal heroin abuse, *J. Am. Acad. Dermatol.*, 1998, 39: 872-875.
11. Barzallo V.J.F., Pulido G.M., Sanabria D.J.A., León D.G. Pénfigo vegetante tipo Hallopeau. Presentación de un caso, *Rev. Med. Hosp. Gen. Mex.*, 2000, 3: 192-195.
12. Pinto G.M., Lamarão P., Vale T. Captopril-induced pemphigus vegetans with Charcot-Leyden crystals, *J. Am. Acad. Dermatol.*, 1992, 27: 281-284.
13. Monshi B., Marker M., Feichtinger H., Schmid G. *et al.* Pemphigus vegetans-immunopathological findings in a rare variant of pemphigus vulgaris, *J. Dtsch. Dermatol. Ges.*, 2010, 8: 179-183.
14. Bastiaens M.T., Zwan N.V., Verschueren G.L., Stoof T.J. *et al.* Three cases of pemphigus vegetans: induction by enalapril-association with internal malignancy, *Int. J. Dermatol.*, 1994, 33: 168-171.
15. Huang Y., Wang S., Kuo T., Chi C. Pemphigus vegetans occurring in a split-thickness skin graft, *Dermatol. Surg.*, 2005, 31: 240-243.
16. Fairley J.A., Woodley D.T., Chen M., Giudice G.J. *et al.* A patient with both bullous pemphigoid and epidermolysis bullosa acquisita: an example of intermolecular epitope spreading, *J. Am. Acad. Dermatol.*, 2004, 51: 118-122.
17. Mignogna M.D., Fortuna G., Leuci S., Stasio L. *et al.* Lichen planus pemphigoides, a possible example of epitope spreading, *Oral Surg., Oral Med., Oral Pathol., Oral Radiol. Endod.*, 2010, 109: 837-843.
18. Marini M.A., Remorino L., Ubaldini G., Magariños G. Penfigoide de las mucosas. Presentación de dos casos clínicos y actualización del tema, *Rev. Argent. Dermatol.*, 2004, 2: 117-122.
19. De Almeida H.L., Neugebauer M.G.P., Guarenti I.M., Aoki V. Pemphigus vegetans associated with verrucous lesions: expanding a phenotype, *Clinics*, 2006, 61: 279-282.
20. Serwin A.B., Bokinić E., Chodynicka B. Pemphigus vegetans in a patient with lung cancer, *Dermatol. Online. J.*, 2005, 11: 13.
21. Török L., Husz S., Ocsai H., Krischner A. *et al.* Pemphigus vegetans presenting as acrodermatitis continua suppurativa, *Eur. J. Dermatol.*, 2003, 13: 579-581.
22. Ma D.L., Fang K. Hallopeau type of pemphigus vegetans confined to the right foot: case report, *Chin. Med. J. (Engl)*, 2009, 122: 588-590.
23. Breton A.L., Chandeclerc M.L., Lefaure C., Cuny J.F. *et al.* Pemphigus vegetans, *Ann. Dermatol. Venereol.*, 2008, 135: 798-799.
24. Sawai T., Kitazawa K., Danno K., Sugie N. *et al.* Pemphigus vegetans with oesophageal involvement: successful treatment with minocycline and nicotinamide, *Br. J. Dermatol.*, 1995, 132: 668-670.
25. Lateef A., Puckles M.R., White S.M., Don P.C. *et al.* Pemphigus vegetans in association with human immunodeficiency virus, *Int. J. Dermatol.*, 1999, 38: 778-781.
26. Iwata M., Watanabe S., Tamaki K. Pemphigus vegetans presenting as scrotal tongue, *J. Dermatol.*, 1989, 16: 159-160.
27. Danopoulou I., Stavropoulos P., Stratigos A., Chatziolou E. *et al.* Pemphigus vegetans confined to the scalp, *Int. J. Dermatol.*, 2006, 45: 1008-1009.
28. Matsubara M., Tamaki T., Sato M., Yasuno H. *et al.* An unusual form of pemphigus vegetans, *Acta Derm. Venereol.*, 1981, 61: 259-261.
29. Mascarenhas R., Fernandes B., Reis J.P., Tellechea O. *et al.* Pemphigus vulgaris with nail involvement presenting with vegetating and verrucous lesions, *Dermatol. Online J.*, 2003, 9: 14. 30. Ichimiya M., Nakano J., Muto M. Pemphigus vegetans involving the esophagus, *J. Dermatol.*, 1998, 25: 195-198.
31. Torres T., Ferreira M., Sanches M., Selores M. Pemphigus vegetans in a patient with colonic cancer, *Indian. J. Dermatol. Venereol. Leprol.*, 2009, 75: 603-605.
32. Duparc A., Boivin S., Gilbert D., Piette F. *et al.* Paraneoplastic pemphigus with pemphigus vegetans-like lesions revealing non-Hodgkin lymphoma, *Eur. J. Dermatol.*, 2006, 16: 698-699.
33. Sapadin A.N., Anhalt G.J. Paraneoplastic pemphigus with a pemphigus vegetans-like plaque as the only cutaneous manifestation, *J. Am. Acad. Dermatol.*, 1998, 39: 867-871.
34. Mahé A., Flageul B., Prost C., Intrator L. *et al.* Pemphigus vegetans in an HIV-1-infected man, *Clin. Exp. Dermatol.*, 1994, 19: 447.
35. Kim J., Chavel S., Girardi M., McNiff J.M. Pemphigoid vegetans: a case report and review of the literature, *J. Cutan. Pathol.*, 2008, 35: 1144-1147.
36. Ichimiya M., Yamamoto K., Muto M. Successful treatment of pemphigus vegetans by addition of etretinate to systemic steroids, *Clin. Exp. Dermatol.*, 1998, 23: 178-180.
37. Pearson R.W., O'Donoghue M., Kaplan S.J. Pemphigus vegetans: its relationship to eosinophilic spongiolysis and favorable response to dapson, *Arch. Dermatol.*, 1980, 116: 65-68.
38. Steiner A., Diem E., Rappersberger K. Pemphigus vegetans (Hallopeau) with eosinophilic spongiolysis-successful retinoid therapy, *Hautarzt.*, 1985, 36: 356-359.